

PATIENT

Samantha Porter

SPECIES

Canine

BREED

Coton de Tulear

SEX

FS

AGE

11 years

WEIGHT

11.6

INTERPRETED BY

Remo Lobetti, BVSc,
MMedVet (Med),
PhD, Dipl. ECVIM

IMAGING PERFORMED BY

Dr Americo Abadia

HOSPITAL NAME

Surfside Pet Hospital

REFERRING VET

Dr Americo Abadia

INVOICE

302760

DATE

2/17/22

PRESENTING CLINICAL SIGNS

History: Chronic IBD managed with tylan powder and probiotics and intermittent metronidazole, and low dose prednisolone. Progressive softer fecal consistency. No weight loss but polydipsia

Physical Examination: N/A.

Urinalysis: N/A.

CBC: Normal.

Serum Biochemistry: Elevated ALP activity.

Radiographic Findings: N/A.

ULTRASONOGRAPHIC EXAMINATION OF THE ABDOMEN

Urinary System

Full urinary bladder with a normal appearance and thickness of the wall. Normal anechoic urine. Focal dependent hyperechogenic sediment/small urolith evident.

Normal trigone area, proximal urethra, and iliac blood vessels.

Normal iliac lymph nodes. Ureters not visualized.

Normal renal size (left 3.7 cm, right 4.1 cm) with increased echogenic appearance, some loss of cortico-medullary differentiation, and normal capsule and pelvis.

Reproductive System

N/A.

Adrenal Glands

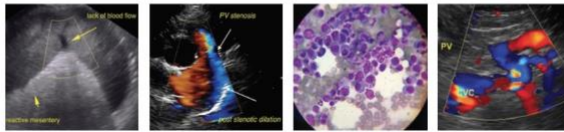
Normal shape, echogenic appearance, size, and position. Left 1.7 x 0.45/0.5 cm, right 1.97 x 0.53/0.46 cm.

Spleen

Normal size and echogenic appearance. Smooth homogenous parenchyma, smooth curvilinear capsule, and normal vasculature. No evidence of inflammatory, neoplastic, infarction, or infiltrative changes noted.

Liver

Normal size with a diffuse hyperechogenic appearance, and some loss of portal markings. Few faint hypoechogenic parenchymal nodules. No masses evident. Full gall bladder containing normal anechoic bile. Normal thickness and appearance of the gall bladder wall. Normal bile duct.



PATIENT

Samantha
Porter

SPECIES

Canine

BREED

Coton de Tulear

SEX

FS

AGE

11 years

WEIGHT

11.6

INTERPRETED BY

Remo Lobetti, BVSc,
MMedVet (Med),
PhD, Dipl. ECVIM

**IMAGING
PERFORMED BY**

Dr Americo Abadia

HOSPITAL NAME

Surfside Pet Hospital

REFERRING VET

Dr Americo Abadia

INVOICE

302760

DATE

2/17/22

Gastrointestinal

Normal appearance of the stomach, ileo-cecal junction, and colon with no loss of layering, normal wall thickness and peristalsis, and no distension of the lumen. Prominent hypoechoic appearance of the submucosal layer of the duodenum and small intestine with patchy mucosal stippling but no loss of layering or distension of the lumen.

Pancreas

Normal size and echogenic appearance. Regular capsule. Normal echogenic appearance of the mesentery and fat surrounding the pancreas.

Free Abdomen

No mesenteric lymphadenomegaly.
No ascites.

ULTRASONOGRAPHIC FINDINGS

Primary findings:

- Enteropathy.
- Hepatopathy.

Secondary findings:

- Age-related renal changes.
- Urinary bladder sediment.

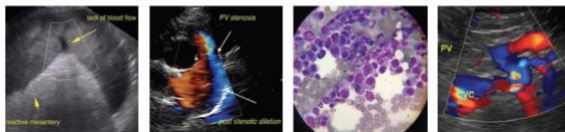
INTERPRETATION OF THE FINDINGS & FURTHER RECOMMENDATIONS

The appearance of the small intestine is in line with the previous diagnosis of inflammatory bowel disease with lymphangectasia, parasitic enteritis, and dietary hypersensitivity, differential diagnoses.

Etiologies for the hepatopathy would be reactive, vacuolar, early nodular regeneration, early cirrhosis, chronic hepatitis, with infiltrative neoplasia a far less likely differential diagnosis.

Further assessment would be urine and fecal analyses, serum cobalamin assay, FNA cytology of the liver, and possibly endoscopy of the upper GI tract with biopsies.

Specific therapy would be dependent on an etiological diagnosis. Symptomatic management would be a novel protein/hypoallergenic diet, course of fenbendazole, cobalamin supplementation, and to continue with prednisolone and/or metronidazole.



PATIENT

Samantha
Porter

SPECIES

Canine

BREED

Coton de Tulear

SEX

FS

AGE

11 years

WEIGHT

11.6

INTERPRETED BY

Remo Lobetti, BVSc,
MMedVet (Med),
PhD, Dipl. ECVIM

IMAGING PERFORMED BY

Dr Americo Abadia

HOSPITAL NAME

Surfside Pet Hospital

REFERRING VET

Dr Americo Abadia

INVOICE

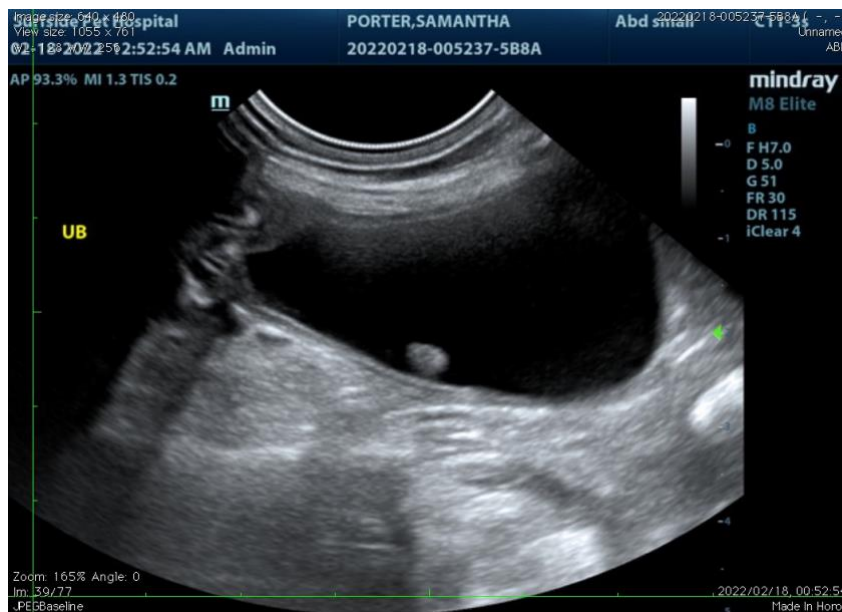302760

DATE

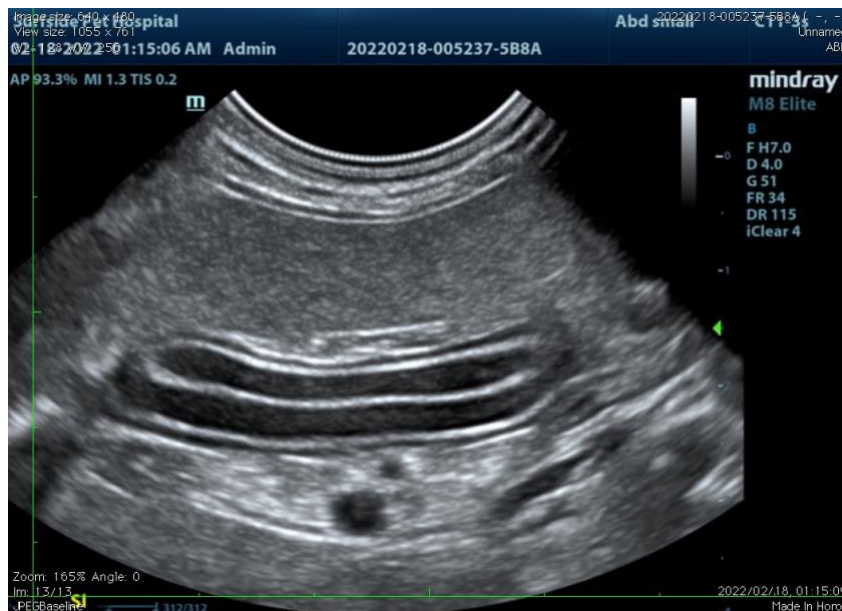2/17/22

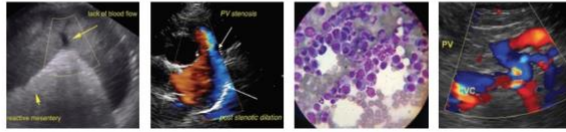
IMAGES

Urinary bladder



Small intestine





PATIENT

Liver

Samantha
Porter

SPECIES

Canine

BREED

Coton de Tulear

SEX

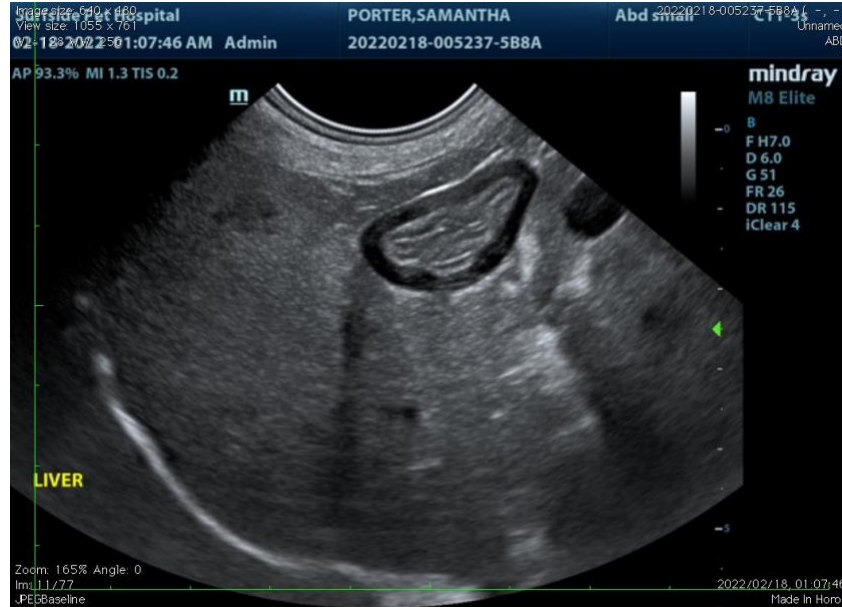FS

AGE

11 years

WEIGHT

11.6



INTERPRETED BY

Remo Lobetti, BVSc,
MMedVet (Med),
PhD, Dipl. ECVIM

The information and recommendations provided are based on the images presented by the referring veterinarian. No evaluation can be communicated regarding pathology that was not visible in the image/video clips provided.

Thank you for this referral. If the clinical or image interpretation does not parallel your findings or if I can be of any further assistance please contact me.

IMAGING PERFORMED BY

Dr Americo Abadia

Remo Lobetti, BVSc, MMedVet (Med), PhD, Dipl. ECVIM (Internal Medicine)
rlobetti@mweb.co.za

HOSPITAL NAME

Surfside Pet Hospital

REFERRING VET

Dr Americo Abadia

INVOICE

302760

DATE

2/17/22